

# Minimally invasive hydraulic elevation of the Schneiderian membrane and insertion of bone graft material using a novel self-tapping implant system: Radiographic and prosthetic aspects

## Abstract

### Objective

The objective of this article was to report the clinical and radiographic performance of a novel implant system that allows for hydraulic Schneiderian membrane elevation and simultaneous bone graft augmentation.

### Case description

A 63-year-old female patient presenting with compromised fixed dental prostheses supported by failing teeth in her posterior maxilla underwent transcrestal sinus floor elevation using a novel implant system. Implant failure, any complications and bone gain measured using cone beam computed tomography (CBCT) were assessed.

### Results

The residual alveolar ridge height was 3.2 mm. A 14.5 mm length implant was placed and followed for 20 months. Bone gain was 18.5 mm after a healing period of eight months. One year after implant loading, CBCT scans showed the stability of the grafted material.

### Conclusion

Hydraulic elevation of the Schneiderian membrane using the iRaise sinus lift system (Maxillent, Herzliya, Israel) can be considered a valuable treatment option for the rehabilitation of atrophic edentulous posterior maxillae.

### Keywords

Dental implant, sinus lift, Schneiderian membrane, atrophic maxilla, bone augmentation.

Marco Tallarico,<sup>a, b</sup> Erta Khanari,<sup>c</sup> Paolo Paglia<sup>d</sup> & Silvio Mario Meloni<sup>b</sup>

<sup>a</sup> Private practice, Rome, Italy

<sup>b</sup> Dentistry Unit, University Hospital of Sassari, Sassari, Italy

<sup>c</sup> Private practice, Tirana, Albania

<sup>d</sup> Private dental laboratory, Rome, Italy

### Corresponding author:

**Dr. Marco Tallarico**

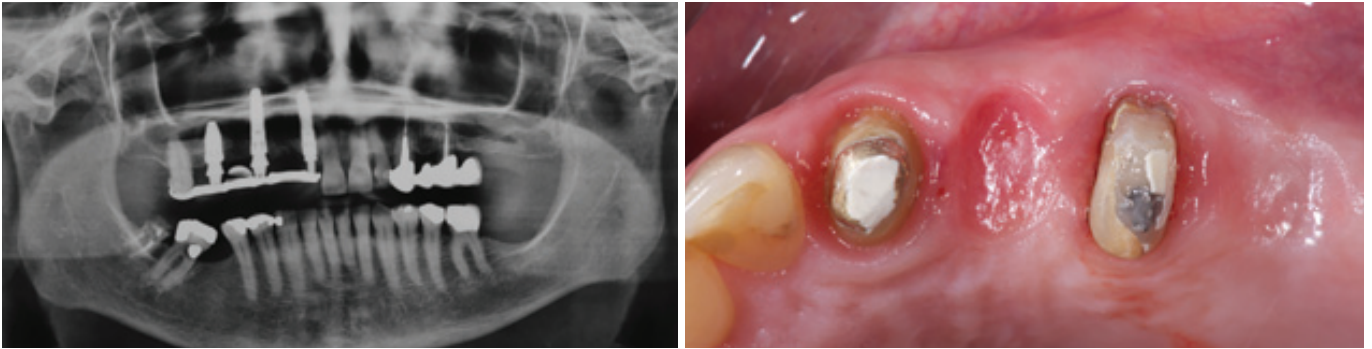
Via di Val Tellina 116  
00151 Rome  
Italy

T +39 328 075 8769  
me@studiomarcotallarico.it

### How to cite this article:

Tallarico M, Khanari E, Paglia P, Meloni SM. Minimally invasive hydraulic elevation of the Schneiderian membrane and insertion of bone graft material using a novel self-tapping implant system: radiographic and prosthetic aspects. *J Oral Science Rehabilitation*. 2016 Sep;2(3):8–14.

Figs. 1 &amp; 2



## Introduction

In the posterior sextants of the maxilla, tooth loss is generally associated with alveolar bone loss and sinus pneumatization.<sup>1</sup> In addition, poor bone quality may have a negative influence on the survival rate of implants.<sup>2</sup> There is no consensus on treatment for the atrophic posterior maxilla, with the dilemma of whether to place short implants<sup>3,4</sup> or tilted implants<sup>5,6</sup> or to augment the floor of the maxillary sinus.<sup>7,8</sup> In a recent review of the literature, Pjetursson et al. reported that the placement of dental implants in combination with maxillary sinus floor elevation using a lateral approach is a predictable treatment option showing high medium-term implant survival rates and low incidences of complications.<sup>7</sup> However, the lateral approach to the sinus entails elevation of a large mucoperiosteal flap that affects postoperative recovery of the patient and the additional expense of the augmentation procedure.<sup>9</sup> Schneiderian membrane perforations, nose bleeding, postoperative pain and swelling could be considered major risks.<sup>10</sup> The elevation of the maxillary sinus floor through the alveolar crest (transalveolar) was first described by Tatum<sup>11</sup> and modified by Summers.<sup>12</sup> Subsequently, various modifications to the original technique have been reported, in order to improve the predictability and safety, such as the use of atraumatic lifting drills,<sup>13</sup> membrane elevation via inflation of a balloon catheter,<sup>14</sup> and the use of hydraulic<sup>15</sup> or negative pressure.<sup>16</sup>

The aim of this clinical report was to present a novel self-tapping endosseous implant system (iRaise, Maxillent, Herzliya, Israel) developed for sinus augmentation. The advantage of this system is the ability to perform major sinus lift augmentation via a minimally invasive transcrestal approach and to simultaneously place an implant, with minimal patient discomfort and shortened treatment time.

## Case presentation

A 63-year-old female patient presented with compromised fixed dental prostheses supported by failing teeth in her posterior maxilla (**Figs. 1 & 2**). The patient reported esthetic concerns and impairment of her masticatory function; consequently, she desired replacement of the prostheses. A cone beam computed tomography (CBCT) scan was performed to evaluate the amount of residual bone. On the right side, conventional implant placement was planned. However, on the left side, the distance from the maxillary crest to the sinus floor was 3.2 mm, requiring a bone augmentation procedure. After detailed consultation, various treatment options were discussed with the patient. Closed major sinus floor augmentation with a transcrestal approach using the iRaise implant system was planned for the maxillary left first molar position to support a screw-retained fixed dental prosthesis. An adjunctive implant was planned for the maxillary left first premolar position.

The day before the implant placement, the patient underwent intranasal spray therapy (thiamphenicol glycinate acetylcysteinate, 810 mg/4 mL) b.i.d. One hour before surgery, a single dose of antibiotic (2 g of amoxicillin and clavulanic acid) was administered prophylactically. A 0.2% chlorhexidine mouthwash was administered for 1 min prior to the implantation procedure.

Local anesthesia was administered (articaine with 1:100,000 epinephrine) and a small full-thickness mucoperiosteal flap was elevated. A 2 mm diameter round bur was used to mark the implant site. The osteotomy was prepared with a 2 mm twist drill 1 mm below the sinus floor. A periapical radiograph with a depth guide was performed in order to verify the drilling angle and depth, as well as the distance to the sinus floor. The implant recipient site was wide-

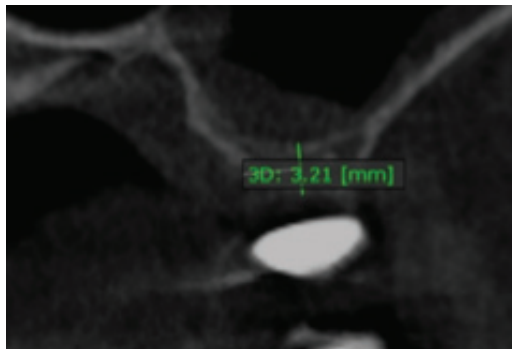
**Fig. 1**

Preoperative panoramic radiograph.


**Fig. 2**

Alveolar ridge before implant placement (occlusal view).

**Fig. 3**  
Preoperative CBCT scan.

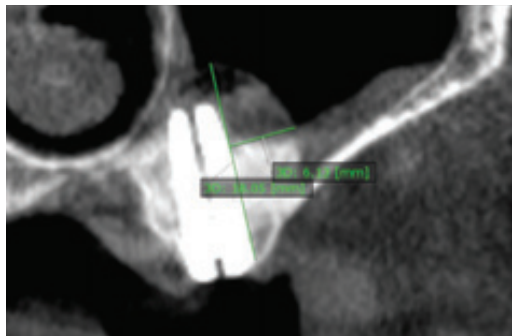


**Fig. 4**  
The iRaise sinus-lift system (Maxillent, Herzliya, Israel).

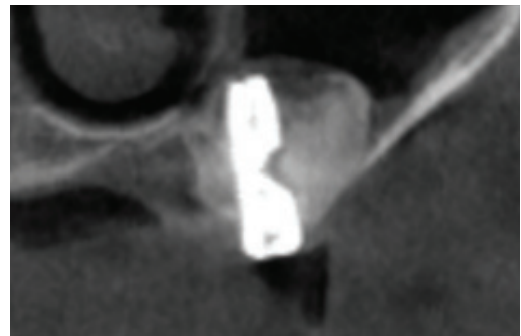


Figs. 3 & 4

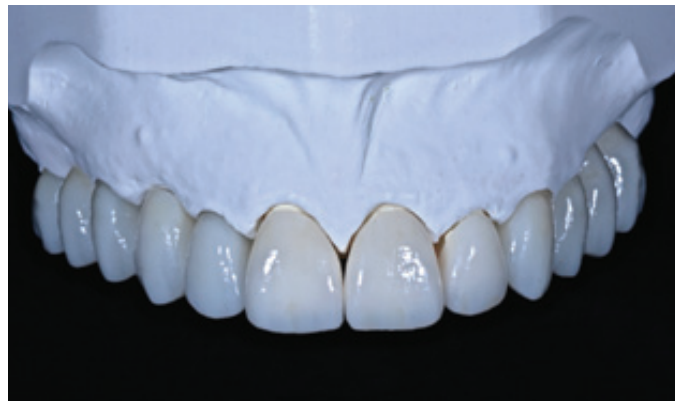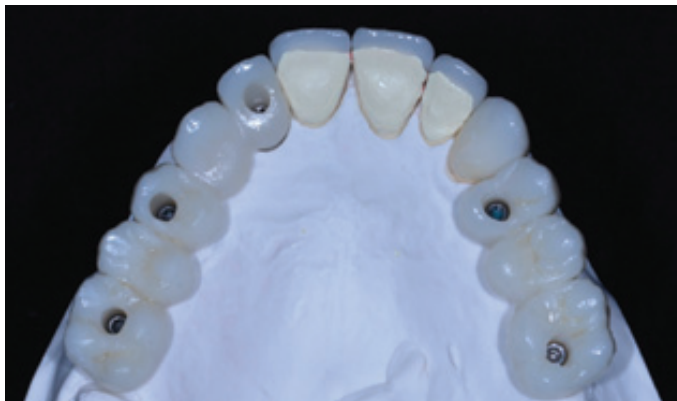**Fig. 5**  
CBCT scan immediately after implant placement.



**Fig. 6**  
CBCT scan six months after implant placement.



Figs. 5 & 6



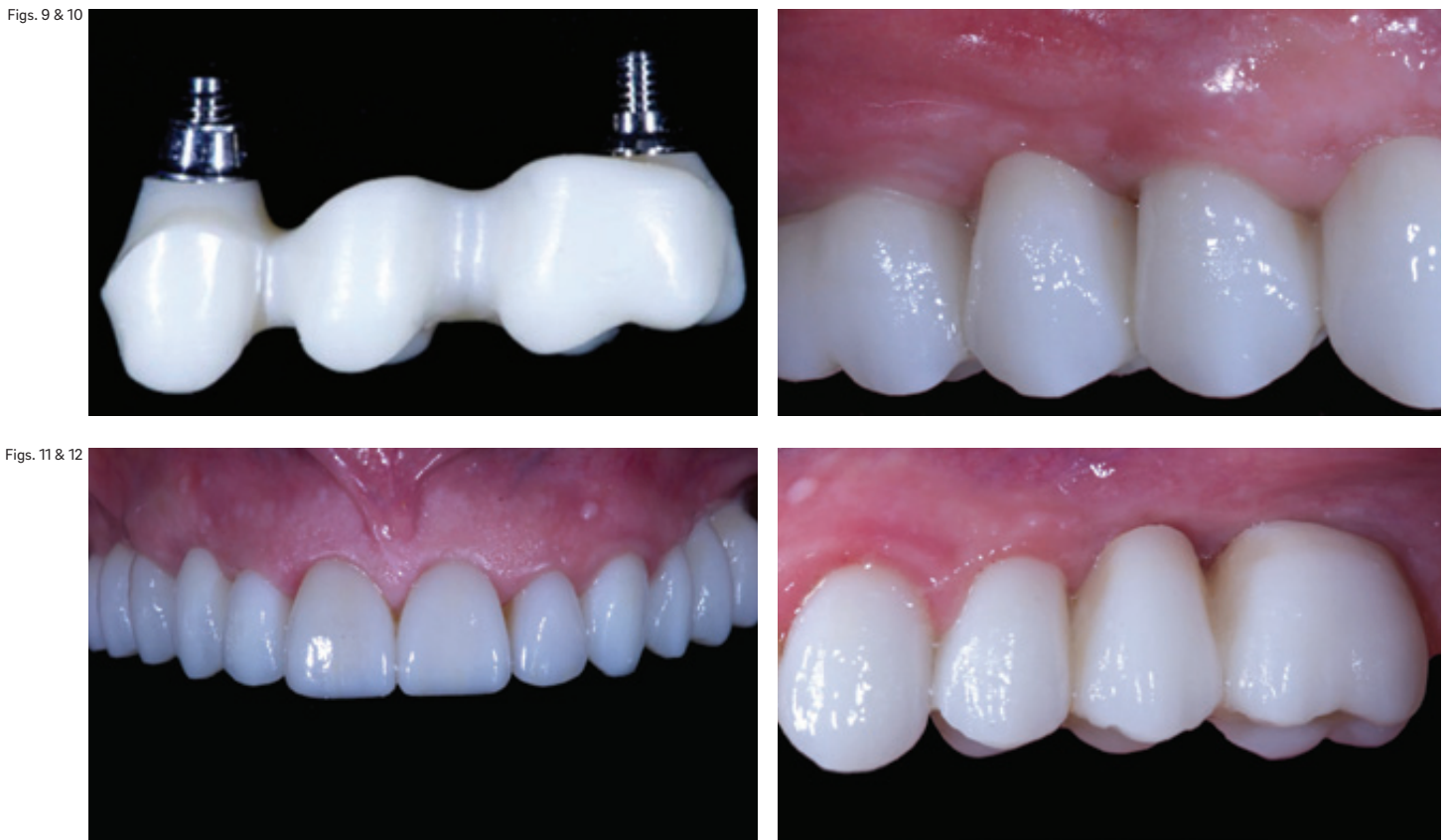Figs. 7 & 8

**Fig. 7**  
Definitive prostheses on the cast (occlusal view).

**Fig. 8**  
Definitive prostheses on the cast (frontal view).

ned to allow the placement of a 5 mm diameter implant, according to the drilling protocol suggested by the manufacturer and reported in a previously published paper.<sup>17</sup> The length of the implant was selected beforehand based on the residual bone height, measured using the preoperative CBCT scan, from the bone crest to the sinus floor, along the implant's planned axis. A 14.50 mm length implant (iRaise, Maxillent, Herzliya, Israel) was used according to a residual bone height of 3.21 mm (**Fig. 3**). The implant was first inserted into the osteotomy until it reached the end of the prepared site. The implant was then slowly advanced until the sinus floor was penetrated for approximately 1 mm. A periapical radiograph was performed in order to determine whether the implant had penetrated the sinus floor. A saline syringe with 2–3 cm<sup>3</sup> of a 0.9% sterile saline solu-

tion was connected to the implant through the tubing port. With this system, the tube connector is easily assembled on the implant, allowing injection of fluids with a standard Luer lock connector. Saline solution was gently injected through the implant and into the sinus and slight bleeding was noted in the retracted saline solution upon stopping the injection. A syringe containing 2 cm<sup>3</sup> of a flowable bone graft material (MBCP Gel, Biomat-lante, Vigneux-de-Bretagne, France) was subsequently connected to the same port. The material was slowly injected through the implant into the sinus (**Fig. 4**). After the grafting procedure had been completed, the hydraulic system was disconnected from the implant, and the implant was inserted to its entire length into the osteotomy and the grafted sinus cavity and left to heal according to a submerged protocol. An additional implant



Figs. 9 &amp; 10

Figs. 11 &amp; 12

was placed after completing the iRaise surgical sequence. A postoperative CBCT scan was taken with reduced voxel size, field of view and milliamperage settings (Fig. 5). After surgery, intranasal spray therapy (thiamphenicol glycinate acetylcysteinate, 810 mg/4 mL) was continued for ten days, an antibiotic (1 g of amoxicillin and clavulanic acid b.i.d.) for six days and a 0.2% chlorhexidine mouthwash (1 min b.i.d.) for two weeks. A soft diet was recommended for one week, while 1 g of paracetamol was prescribed in case of pain. The sutures were removed after one week, and oral hygiene instructions were emphasized.

Six months after implant placement, a CBCT scan was taken with the same parameters used for the postoperative scan, and the healing abutments were connected. The bone gain was 18.5 mm (Fig. 6). Definitive screw-retained metal-free restorations were delivered eight months after implant placement (Figs. 7–9). The occlusion was carefully checked. Recall appointments for oral hygiene maintenance and oral hygiene instructions were set for every four months after loading. The occlusion was evaluated at each visit. CBCT scans were performed one year after implant loading (20 months after implant placement) and compared with the previously taken CBCT scans (Figs. 10–16).

## Discussion

The present case report is one of the first aimed at evaluating a novel implant system that allows for minimally invasive major sinus floor elevation at the time of implant placement. According to a recent Cochrane systematic review, if the residual alveolar bone height is 3–6 mm, a transcrestal approach to lifting the Schneiderian membrane and placing 8 mm implants may lead to fewer complications than would a lateral window approach and placing implants at least 10 mm long.<sup>19</sup>

In the case presented, the patient experienced minimal discomfort and was functionally restored in a shorter period than are patients treated with a two-stage sinus grafting technique. In investigating the transcrestal osteotome technique for sinus floor augmentation, some researchers have recorded high rates of patient satisfaction.<sup>7, 20, 21</sup> Maxillary sinus floor elevation with a transcrestal approach is advocated as a minimally invasive procedure, owing to the minimal surgical flap required. Moreover, the lateral sinus wall remains intact, reducing postoperative morbidity.<sup>22, 23</sup> This technique is widely documented in the literature

Fig. 9

Metal-free framework.

Fig. 10

Right lateral view of the definitive prosthesis taken one year after loading.

Fig. 11

Frontal view of the definitive prosthesis taken one year after loading.

Fig. 12

Left lateral view of the definitive prosthesis taken one year after loading.

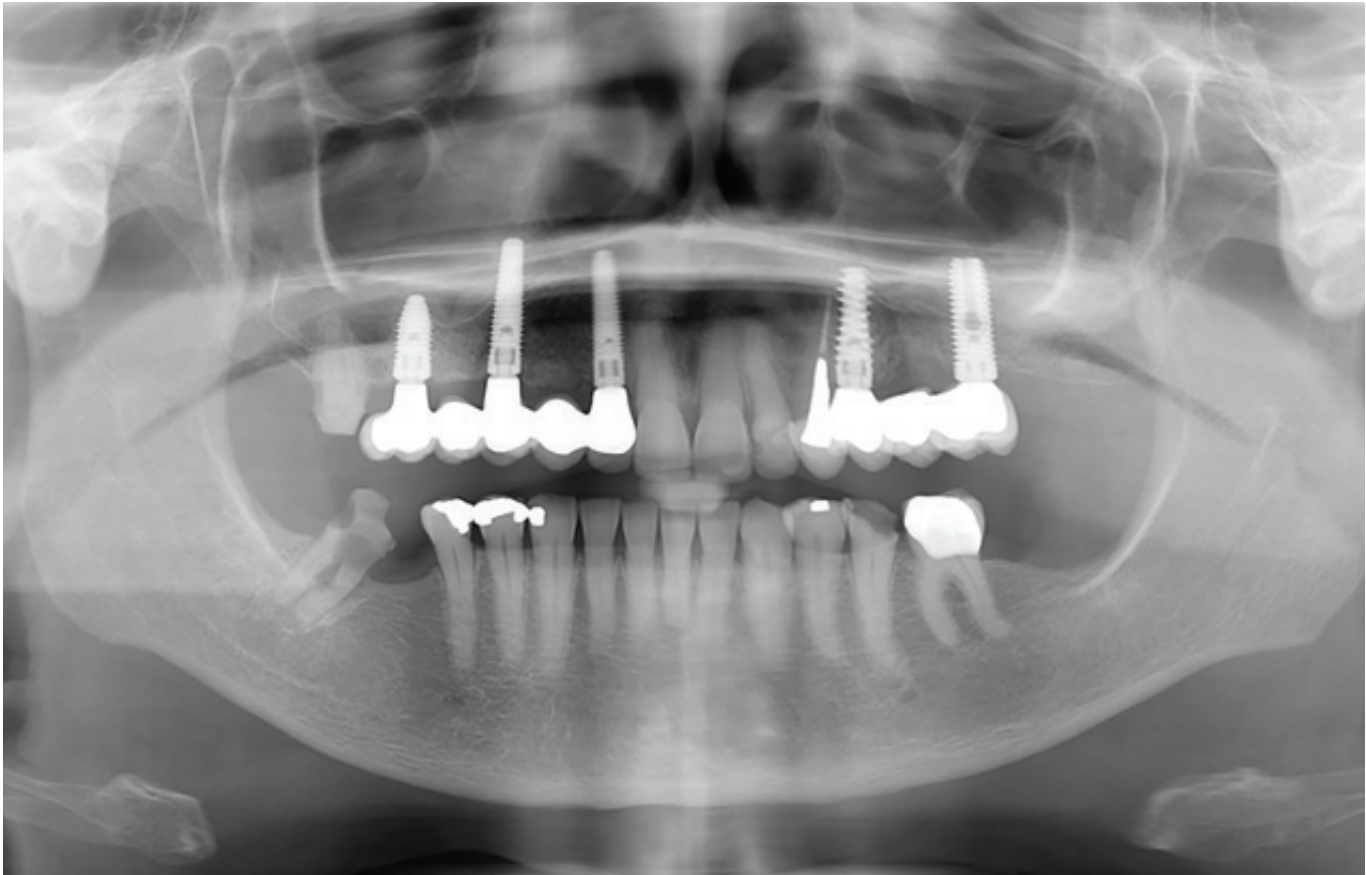
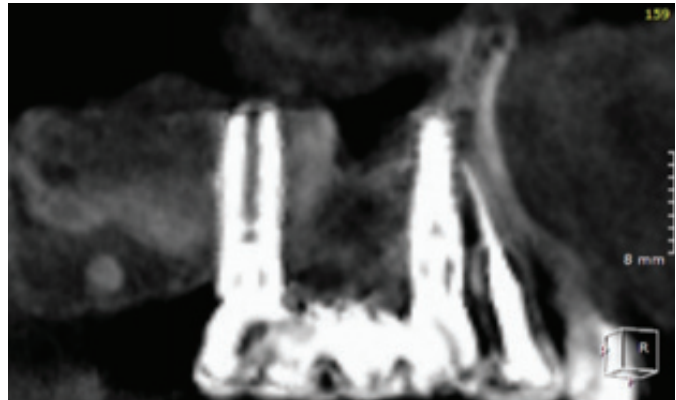
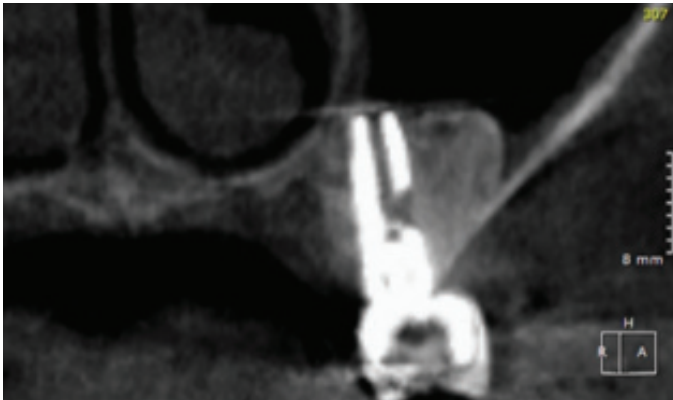


Fig. 13



Figs. 14 & 15

**Fig. 13**  
Panoramic radiograph taken one year after loading.

**Fig. 14**  
CBCT scan one year after loading (sagittal view).

**Fig. 15**  
CBCT scan one year after loading (coronal view).

and supported by several longitudinal studies that attest to an average implant survival rate close to 92% in the medium term.<sup>7, 8, 24</sup> Recent publications have shown that transalveolar sinus floor elevation is a reliable method for implant placement in the posterior maxilla, even at sites with  $\leq 4$  mm of residual alveolar bone height.<sup>17, 25-27</sup> Nevertheless, implant survival rates may decrease with reduced residual bone height.<sup>18, 28</sup>

The main concerns related to the transcresal approach, compared with the lateral surgical approach, are the absence of direct visualization

of the sinus cavity and Schneiderian membrane, the limited amount of bone augmentation achieved and the high risk of inadvertent perforation of the Schneiderian membrane during fracture of the sinus floor with osteotomes, or burs, with or without stop drills, without the possibility of repairing the torn membrane. Nevertheless, in an eight-year retrospective study on 1,100 participants with 1–5 mm of residual bone height who received 1,557 implants with minimally invasive hydraulic elevation of the Schneiderian membrane, an incidence of membrane perforation of less than 0.5 % was reported.<sup>15</sup>

Fig. 16

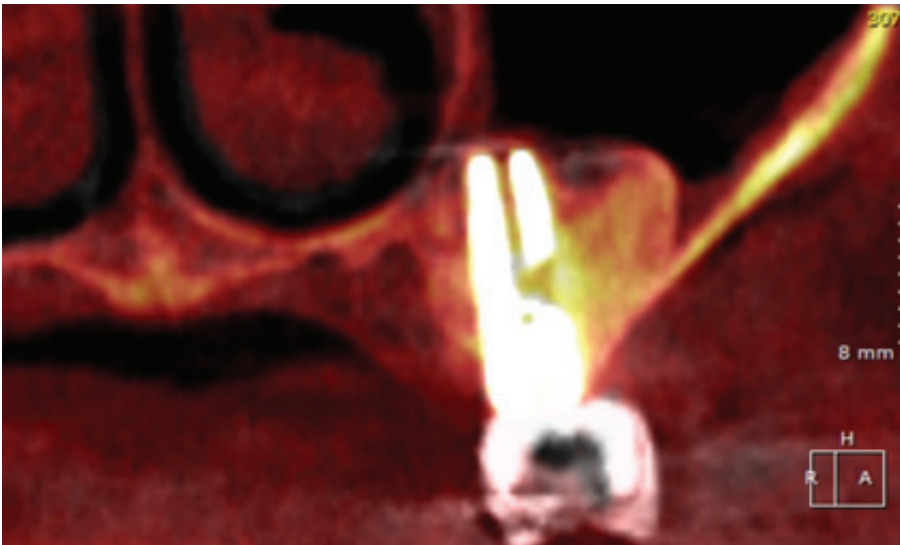


Fig. 16

Superimposition of the CBCT scans taken six months after implant placement (red) and one year after loading (gray) showing stability of the grafted material over time.

The iRaise implant system is a uniquely designed implant housing an L-shaped channel separate from the prosthetic connection and the oral cavity, thereby eliminating the possibility of bacteria migrating into the bone. Through this channel, saline is introduced to elevate the Schneiderian membrane. The iRaise system allows the clinician to perform a minimally invasive sinus augmentation procedure immediately. The hydraulic elevation of the Schneiderian membrane and the insertion of bone graft material are performed through the implant itself, resulting in fewer complications, shorter treatment time and greater comfort for patients, compared with the open sinus lift procedure.

Closed major sinus floor augmentation with a transcrestal approach can be accomplished using a novel system that allows for hydraulic elevation of the Schneiderian membrane, injection of a flowable bone graft material and simultaneous dental implant placement, with minimal patient discomfort. Long-term clinical studies on larger cohorts of patients are needed to confirm these preliminary results.

### Competing interests

This was an investigator-initiated trial. The trial was supported partially by Maxillent.

### Acknowledgments

The authors wish to thank Maxillent (Herzliya, Israel) for its partial support of this trial and provision of the implants and prosthetic components. The authors also wish to thank the staff of the dental laboratory (Odontotecnica Paglia & Moretti, Rome, Italy) who manufactured the definitive prostheses.

## References

1. Wallace SS, Froum SJ. Effect of maxillary sinus augmentation on the survival of endosseous dental implants. A systematic review. → *Ann Periodontol*. 2003 Dec;8(1):328–43.
2. Salimov F, Tatli U, Kürkcü M, Akoğlan M, Öztunç H, Kurtoğlu C. Evaluation of relationship between preoperative bone density values derived from cone beam computed tomography and implant stability parameters: a clinical study. → *Clin Oral Implants Res*. 2014 Sep;25(9):1016–21.
3. Srinivasan M, Vazquez L, Rieder P, Moraguez O, Bernard JP, Belser UC. Efficacy and predictability of short dental implants (< 8 mm): a critical appraisal of the recent literature. → *Int J Oral Maxillofac Implants*. 2012 Nov–Dec;27(6):1429–37.
4. Sun HL, Huang C, Wu YR, Shi B. Failure rates of short ( $\leq 10$  mm) dental implants and factors influencing their failure: a systematic review. → *Int J Oral Maxillofac Implants*. 2011 Jul–Aug;26(4):816–25.
5. Peñarrocha-Oltra D, Candel-Martí E, Ata-Ali J, Peñarrocha-Diago M. Rehabilitation of the atrophic maxilla with tilted implants: review of the literature. → *J Oral Implantol*. 2013 Oct;39(5):625–37.
6. Menini M, Signori A, Tealdo T, Bevilacqua M, Pera F, Ravera G, Pera P. Tilted implants in the immediate loading rehabilitation of the maxilla: a systematic review. → *J Dent Res*. 2012 Sep;91(9):821–7.
7. Pjetursson BE, Tan WC, Zwahlen M, Lang NP. A systematic review of the success of sinus floor elevation and survival of implants inserted in combination with sinus floor elevation. → *J Clin Periodontol*. 2008 Sep;35(8 Suppl):216–40.
8. Meloni SM, Jovanovic SA, Lolli FM, Cassisa C, De Riu G, Pisano M, Lumbau A, Lugliè PF, Tullio A. Grafting after sinus lift with anorganic bovine bone alone compared with 50:50 anorganic bovine bone and autologous bone: results of a pilot randomised trial at one year. → *Br J Oral Maxillofac Surg*. 2015 May;53(5):436–41.
9. Geminiani A, Weitz DS, Ercoli C, Feng C, Caton JG, Papadimitriou DE. A comparative study of the incidence of Schneiderian membrane perforations during maxillary sinus augmentation with a sonic oscillating handpiece versus a conventional turbine handpiece. → *Clin Implant Dent Relat Res*. 2015 Apr;17(2):327–34.
10. Katranji A, Fotek P, Wang HL. Sinus augmentation complications: etiology and treatment. → *Implant Dent*. 2008 Sep;17(3):339–49.
11. Tatum HJ Jr. Maxillary and sinus implant reconstructions. → *Dent Clin North Am*. 1986 Apr;30(2):207–29.
12. Summers RB. A new concept in maxillary implant surgery: the osteotome technique. → *Compendium*. 1994 Feb;15(2):152, 154–6, 158 passim; quiz 162.
13. Cosci F, Luccioli M. A new sinus lift technique in conjunction with placement of 265 implants: a 6-year retrospective study. → *Implant Dent*. 2000 Winter;9(4):363–8.
14. Soltan M, Smiler DG. Antral membrane balloon elevation. → *J Oral Implantol*. 2005 Apr;31(2):85–90.
15. Chen L, Cha J. An 8-year retrospective study: 1,100 patients receiving 1,557 implants using the minimally invasive hydraulic sinus condensing technique. → *J Periodontol*. 2005 Mar;76(3):482–91.
16. Suguimoto RM, Trindade IK, Carvalho RM. The use of negative pressure for the sinus lift procedure: a technical note. → *Int J Oral Maxillofac Implants*. 2006 May–Jun;21(3):455–8.
17. Better H, Slavescu D, Barbu H, Cochran DL, Chaushu G. Minimally invasive sinus lift implant device: a multicenter safety and efficacy trial preliminary results. → *Clin Implant Dent Relat Res*. 2014 Aug;16(4):520–6.
18. Tallarico M, Better H, De Riu G, Meloni SM. A novel implant system dedicate to hydraulic Schneiderian membrane elevation and simultaneously bone graft augmentation: An up-to 45 months retrospective clinical study. → *J Craniomaxillofac Surg*. 2016;44:1089–94. doi:10.1016/j.jcms.2016.05.016.
19. Esposito M, Felice P, Worthington HV. Interventions for replacing missing teeth: augmentation procedures of the maxillary sinus. → *Cochrane Database Syst Rev*. 2014;5:CD008397.
20. Pjetursson BE, Ignjatovic D, Matulienė G, Brägger U, Schmidlin K, Lang NP. Transalveolar maxillary sinus floor elevation using osteotomes with or without grafting material. Part II: radiographic tissue remodeling. → *Clin Oral Implants Res*. 2009 Jul;20(7):677–83.
21. Del Fabbro M, Corbella S, Weinstein T, Ceresoli V, Taschieri S. Implant survival rates after osteotome-mediated maxillary sinus augmentation: a systematic review. → *Clin Implant Dent Relat Res*. 2012 May;14 Suppl 1:e159–68.
22. Chan HL, Oh TJ, Fu JH, Benavides E, Avila-Ortiz G, Wang HL. Sinus augmentation via transcrestal approach: a comparison between the balloon and osteotome technique in a cadaver study. → *Clin Oral Implants Res*. 2013 Sep;24(9):985–90.
23. Bruschi GB, Crespi R, Capparè P, Gherlone E. Transcrestal sinus floor elevation: a retrospective study of 46 patients up to 16 years. → *Clin Implant Dent Relat Res*. 2010 Oct;14(5):759–67.
24. Nkenke E, Stelzle F. Clinical outcomes of sinus floor augmentation for implant placement using autogenous bone or bone substitutes: a systematic review. → *Clin Oral Implants Res*. 2009 Sep;20 Suppl 4:124–33.
25. Ahn SH, Park EJ, Kim ES. Reamer-mediated transalveolar sinus floor elevation without osteotome and simultaneous implant placement in the maxillary molar area: clinical outcomes of 391 implants in 380 patients. → *Clin Oral Implants Res*. 2012 Jul;23(7):866–72.
26. Stavropoulos A, Karring T, Kostopoulos L. Fully vs. partially rough implants in maxillary sinus floor augmentation: a randomized-controlled clinical trial. → *Clin Oral Implants Res*. 2007 Feb;18(1):95–102.
27. Tallarico M, Meloni SM, Khanari E, Pisano M, Cochran DL. Minimally Invasive Sinus Augmentation Procedure Using a Dedicated Hydraulic Sinus Lift Implant Device: A Prospective Case Series Study on Clinical, Radiologic, and Patient-Centered Outcomes. → *Int J Periodontics Restorative Dent*. 2016. doi:10.11607/prd.2914.
28. Rosen PS, Summers R, Mellado JR, Salkin LM, Shanaman RH, Marks MH, Fugazzotto PA. The bone-added osteotome sinus floor elevation technique: multicenter retrospective report of consecutively treated patients. → *Int J Oral Maxillofac Implants*. 1999 Nov/Dec;14(6):853–8.