

Bone augmentation of canine frontal sinuses using a porous α -tricalcium phosphate for implant treatment

Abstract

Objective

Compared with hydroxyapatite, alpha-tricalcium phosphate (α -TCP) is more biodegradable and shows better integration during physiological bone remodeling. The objective of this study was to evaluate the effects of porous α -TCP as a tissue-engineered scaffold for maxillary sinus augmentation in a canine model.

Materials and methods

Porous α -TCP was prepared by pulverizing an α -TCP block with an 80% continuous pore structure. Bilateral sinus floor augmentation surgeries were performed on beagle dogs that were randomly divided into two groups based on the type of repair: The experimental group received a porous α -TCP and titanium (Ti) implant, and the control group received a Ti implant. Periimplant bone volume (BV) and bone mineral content (BMC) were measured and analyzed using micro-computed tomography (micro-CT) and Villanueva–Goldner staining for histological examination. The intergroup differences were evaluated using the Student's *t*-test.

Results

Micro-CT images at 12 weeks after surgery showed higher BV and BMC in the experimental group than in the control group ($p < 0.05$). Histological examination showed high levels of α -TCP even at four weeks, but the scaffolds were completely absorbed and new bone integrated into the Ti implants at 12 and 24 weeks. However, no bone formation was observed in the control group throughout the study.

Conclusion

Porous α -TCP increased BV and promoted bone mineralization and earlier bone formation in the augmented maxillary sinus. Therefore, this tissue-engineered scaffold might be a better alternative to autologous bone for maxillary sinus augmentation.

Keywords

Bone augmentation, porous α -tricalcium phosphate, canine frontal sinuses.

Masataka Hirose,^a Naoya Uemura,^a Yoshiya Hashimoto,^b Isumi Toda^c & Shunsuke Baba^a

^a Department of Oral Implantology, Osaka Dental University, Hirakata, Japan

^b Department of Biomaterials, Osaka Dental University, Hirakata, Japan

^c Department of Anatomy, Osaka Dental University, Hirakata, Japan

Corresponding author:

Dr. Yoshiya Hashimoto

Department of Biomaterials
Osaka Dental University, 8-1
Kuzuhahanazono-cho Hirakata
5731121 Osaka
Japan

yoshiya@cc.osaka-dent.ac.jp

How to cite this article:

How to cite this article: Hirose M, Uemura N, Hashimoto Y, Toda I, Baba S. Bone augmentation of canine frontal sinuses using a porous α -tricalcium phosphate for implant treatment.

J Oral Science Rehabilitation.
2017 Mar;3(1):44–51.

Introduction

Implant placement in highly atrophic maxillae has been a major challenge in implant dentistry. Sinus floor elevation is a preferred option in such situations. Various maxillary sinus floor augmentation techniques have been developed for managing severe bone loss in the maxilla.^{1–4} However, it is important to define the best bone substitute for the subsinus cavity after sinus membrane lift procedures. Although autogenous bone grafting is still considered the gold standard for treatment, it has several disadvantages, including the requirement of a second surgery at the donor site and limited bone supply.^{5, 6} Artificial bone grafts are promising alternatives to autogenous bone grafts.

Synthetic hydroxyapatite (HA) has been widely applied in the medical and dental fields because of its high biocompatibility and osteoconductive properties.^{7, 8} However, the application of HA has to be carefully considered because it is poorly displaced by new bone tissue⁹ and is easily adsorbed by bacteria and epithelial cells because of its high surface energy.^{10, 11} Bovine HA is frequently used as a grafting material in sinus lift procedures because of its features that resemble cancellous bone, complete deproteinization of the inorganic component and thus the absence of antigenicity.¹² Beta-tricalcium phosphate (β -TCP) was one of the earliest calcium phosphate compounds used as a bone graft substitute because of its high osteoconductivity, tissue compatibility and ability to withstand sufficient mechanical stress.¹³ High-temperature TCP, known as α -TCP, is often prepared by sintering amorphous precursors with the proper composition.¹⁴

Marukawa et al. demonstrated the usefulness of self-setting α -TCP (BIOPEX-R) in maintaining the rigidity of implanted bone screws using maxillary sinus augmentation in rabbits.¹⁵ However, a drawback of self-setting bone cement is its weak mechanical property. In a previous study, we fabricated porous α -TCP composites with a continuous small-and-large-pore structure and demonstrated that the composite created using porous α -TCP particles and collagen or collagen model peptide had enough adaptability for treating skull bone defects in miniature pigs.⁵ However, the effectiveness of porous α -TCP particles as a grafting material in sinus lift procedures has not yet been investigated. The objective of this study was to evaluate the effects of porous α -TCP as a tissue-engineered scaffold using a canine frontal sinus model.

Materials and methods

Material analysis

Preparation and characterization of porous α -TCP particles


Porous α -TCP particles with an average diameter of 580.8 μm and porosity of about 80% were obtained from Taihei Chemical Industrial (Osaka, Japan) and sterilized by dry heating before the experiment. A field-emission scanning electron microscope (S-4100, Hitachi High-Technologies Corporation, Tokyo, Japan) was used to analyze particle size, pore distribution and outer surface conditions. Before observation, samples were coated with platinum–palladium using the E-1030 (Hitachi High-Technologies Corporation). α -TCP particles were characterized using a powder X-ray diffraction system (XRD; XRD-6100, Shimadzu, Kyoto, Japan). XRD patterns were obtained with the following parameters: 40 kV, 30 mA, scan rate of 2°/min and step size of 0.05° within a range of 10–60°. Crystal phase was characterized using data from the International Centre for Diffraction Data (HA: 9-0432; α -TCP: 9-0348). X-ray photoelectron spectroscopy (XPS) measurements were performed to determine the surface Ca/P atomic ratios with a PHI X-tool (Ulvac-Phi, Chigasaki, Japan) equipped with an Al-K α radiation source (15 kV; 53 W; spot size of 205 μm) at a pass energy of 280.0 eV, a step size of 0.1 eV and a takeoff angle of 45° with 20 scans.

Animal models

The mandibular defect model was established using six healthy beagles (2 years old; weighing approximately 10 kg) obtained from Hamaguchi Animal (Osaka, Japan). The animals were housed in a temperature-controlled environment at 24 °C with free access to food and water. The body weight and general health of the animals were monitored throughout the study.

α -TCP particle transplantation

The dogs underwent bilateral sinus floor augmentation surgeries and were randomly divided into two groups depending on the type of repair: The experimental group received a porous α -TCP and tapered titanium (Ti) implant (NovelActive, Nobel Biocare Japan, Tokyo, Japan), and the control group received the



Figs. 1a & b

Figs. 1a & b

Scanning electron micrograph of porous α -TCP particles:

- (a) low-magnification image;
(b) high-magnification image.

Ti implant alone. All procedures in this study were approved by the Animal Experiment Committee of Osaka Dental University and conformed to the Guiding Principles for the Use of Laboratory Animals (approval No. 14-03015). Aseptic surgery was performed under general anesthesia (0.5 mg/kg pentobarbital sodium) with physiological saline cooling and infiltration anesthesia (1.8 mL of 2% lidocaine hydrochloride and 1:80,000 epinephrine). The hair from the frontal region was removed, and the skin including the frontal sinus was incised in the shape of an arc. The skin–periosteal flap was detached, and the anterior wall of the frontal sinus was exposed. Then, an approximately 10 mm wide rectangular opening was made in the anterior wall of the left and right frontal sinuses using a twist drill (Astra Tech, Tokyo, Japan). In addition, porous α -TCP particles (2.7 cm³) were filled in this elevation space. The Ti implant was embedded at a distance of about 5 mm from the bony window. The anti-inflammatory agent carprofen (Carprofyl VR, Ceva, Libourne, France) was administered daily for seven days after the surgery.

Radiographic analysis

The maxillae were harvested for examination by micro-computed tomography (micro-CT; SMX-130CT, Shimadzu). Blocks of bone specimens were mounted on the turntable and scanned at 105 kV and 30 μ A. TRI/3D-BON software (RATOC System Engineering, Tokyo, Japan) was used to generate a 3-D reconstruction using the volume-rendering method for morphological assessment. In the 3-D analysis, bone volume (BV in mm³) and bone mineral content (BMC in

mg) were measured using the TRI/3D-BON software based on the values obtained.

Histological assessment

After fixation with 10% phosphate-buffered formalin, the specimens with the Ti implant were dehydrated in ethanol and then embedded in acrylic resin (Technovit 7200 VLC, Heraeus Kulzer, Wehrheim, Germany). The embedded blocks were trimmed using a cutter and ground using abrasive paper. Thereafter, the sections were further ground to a final thickness of about 30 μ m. Finally, the specimens were stained with the Villanueva–Goldner stain and examined under a microscope.

Results

Characterization of α -TCP particles

Figure 1 shows the electron micrographs of α -TCP particles. At low magnification, the α -TCP particles had an amorphous body with many small and large pores (**Fig. 1a**). At high magnification, the α -TCP particles had smooth surfaces with a pore diameter of approximately 5–10 μ m. The XRD profiles of both intact particles are shown in **Figure 1b**. The specific peaks of α -TCP (indicated by the triangles) were detectable in the XRD patterns of both particles (**Fig. 2**). For XPS, quantitative data of the atom% were obtained from the peak areas derived for O1s, Ca2p, P2p and C1s, from which the Ca/P ratio was calculated and found to be 1.5 (**Fig. 3**).

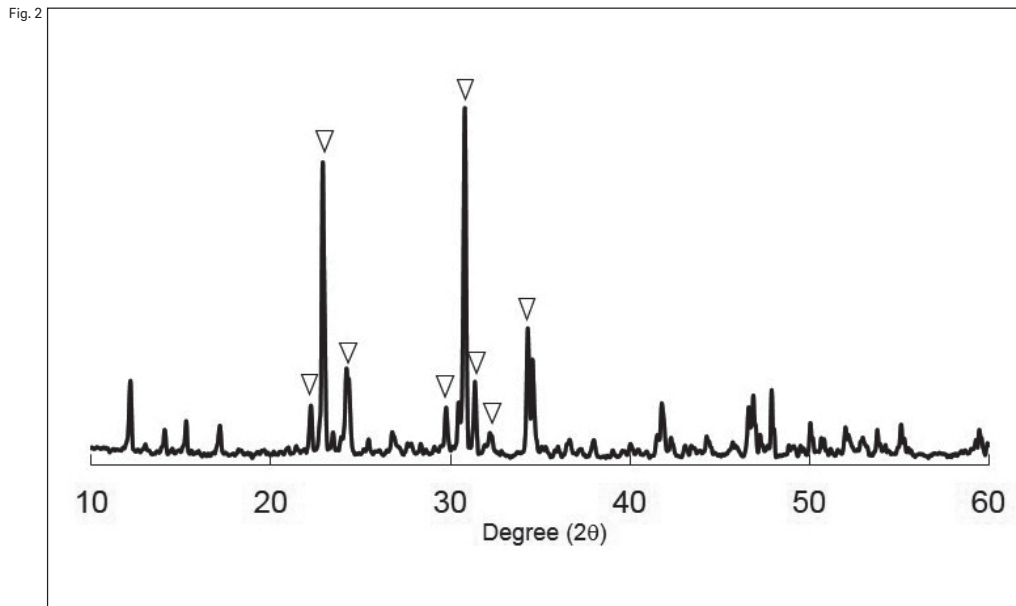


Fig. 2
XRD pattern of porous α -TCP particles. Triangles show α -TCP peaks.

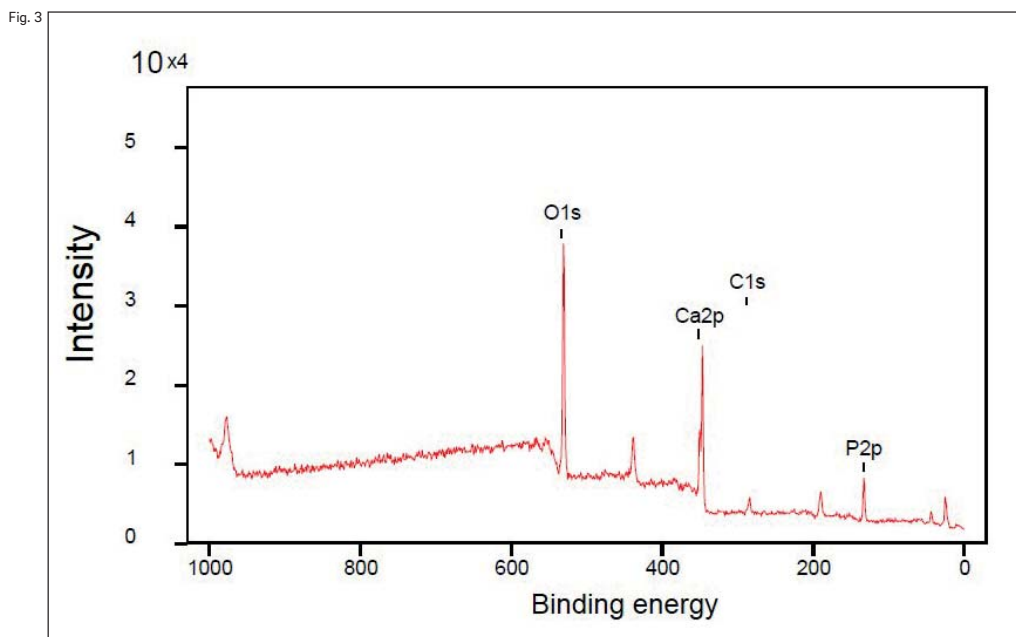


Fig. 3
Wide X-ray photoelectron spectra of porous α -TCP particles.

Radiographic analysis

A quantitative imagology analysis of the bone window areas of the specimens was carried out at four, 12 and 24 weeks using micro-CT (**Fig. 4**). In the experimental group, newly formed bone was observed in the area of the bone window; however, bone formation reduced between 12 and 24 weeks. In the control group, the area of the bone window was empty, although some new bone formation was observed toward the edges of the bone window.

BV and BMC analysis

BV and BMC of each group were determined at four, 12 and 24 weeks (**Fig. 5**). BV and BMC were higher in the experimental group than in the control group at 12 weeks ($p < 0.05$). No significant intergroup differences were observed in either analysis at four or 24 weeks ($p > 0.05$; **Fig. 5**).

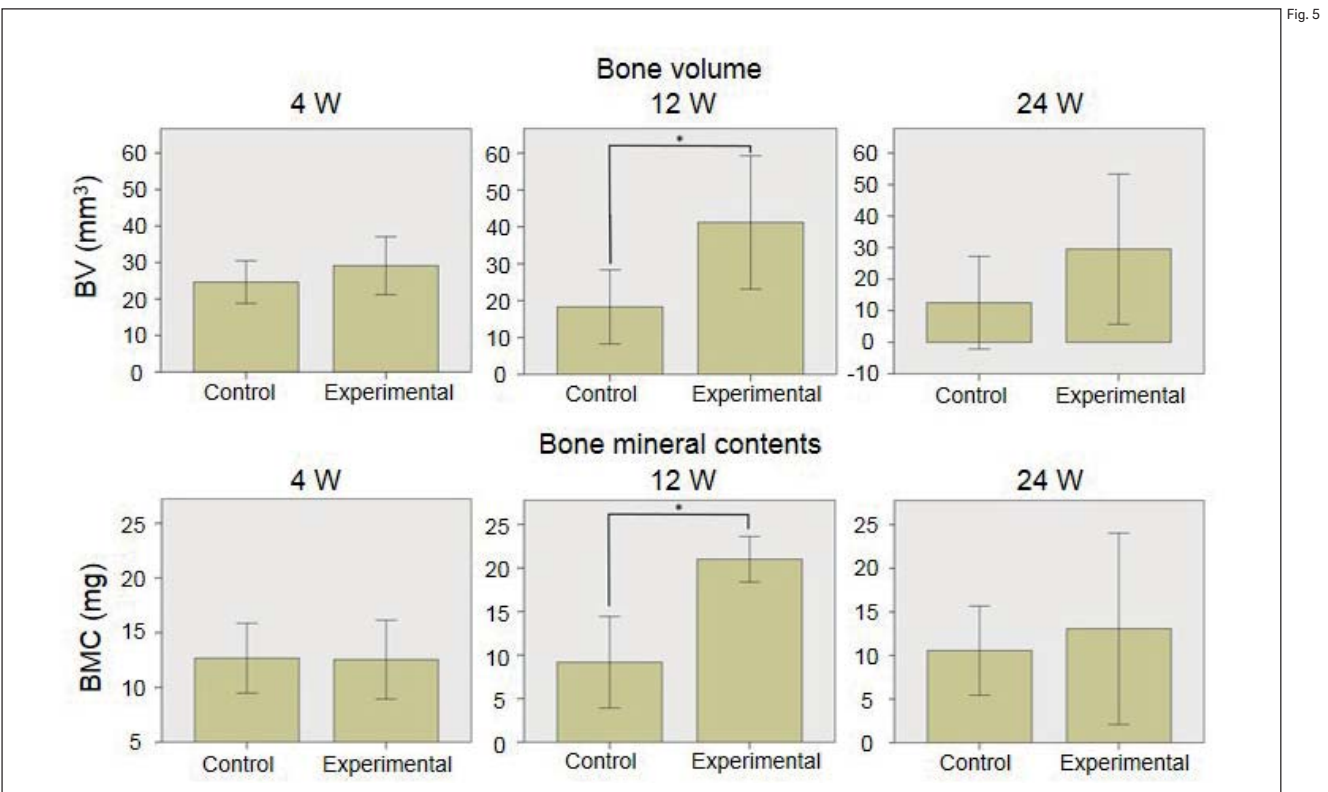
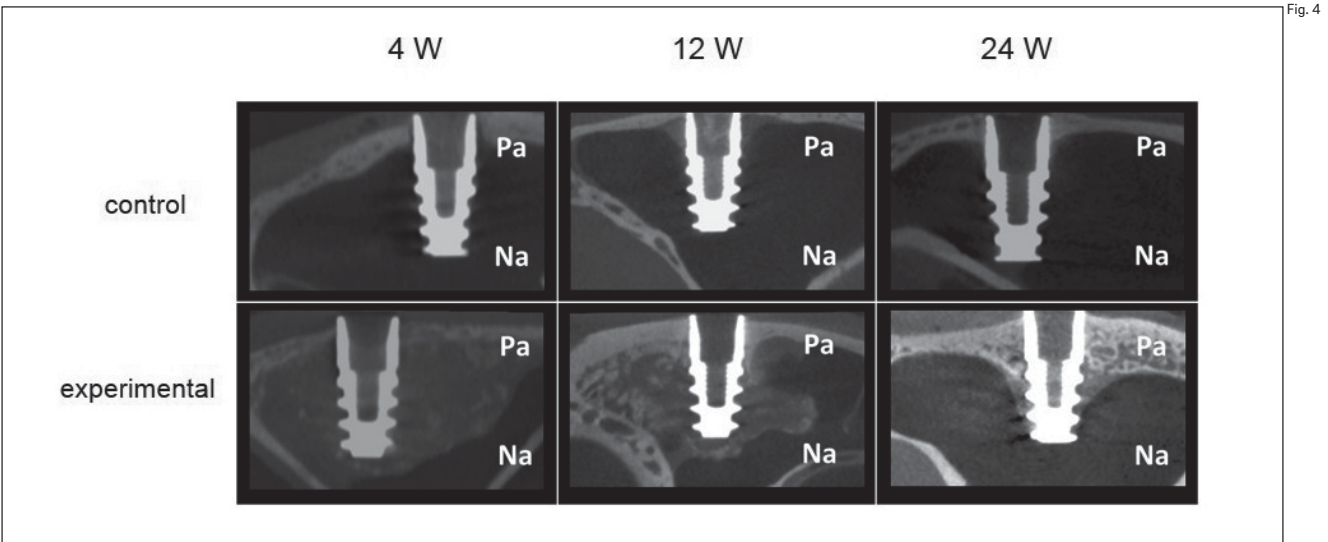


Fig. 4
Micro-CT images acquired at four, 12 and 24 weeks after surgery. (PA = palatal side; NA = nasal side).

Fig. 5
The upper and lower groups show BV (mm³) and BMC (mg) of each group, reflecting the quantity of new bone at four, 12 and 24 weeks after surgery.

Histological assessment

Histological assessments were also performed at four, 12 and 24 weeks (Figs. 6 & 7). Histological images showed high levels of porous α -TCP even at four weeks; however, the scaffolds had completely absorbed and new bone integrated into the Ti implants at 12 and 24 weeks. The

formation of new bone in the area of the bone window reduced between 12 and 24 weeks; however, the newly formed bone had changed to mature bone (Fig. 6). Although no bone formation was observed in the control group throughout the study, some new bone formation was observed toward the edges of the bone window (Fig. 7).

Fig. 6




Fig. 6

Low- and high-magnification images in the experimental group, demonstrating new bone formation in the upper and lower groups at 4, 12 and 24 weeks after surgery. Red asterisks show the residual porous α -TCP particles. Each black bar of the low- and high-magnification images shows 1,000 and 500 μ m, respectively.

Fig. 7




Fig. 7

The low- and high-magnification images in the control group, demonstrating new bone formation in the upper and lower groups at 4, 12 and 24 weeks after surgery. Each black bar of the low- and high-magnification images shows 1,000 and 500 μ m, respectively.

Discussion

α -TCP is widely considered an option for use as a bone grafting material. However, few studies have used porous α -TCP particles for sinus lift with tissue engineering techniques. In order to maximize the surface area for cell attachment and proliferation, we fabricated the scaffold into

a highly porous 3-D structure through a relatively simple processing method involving a conventional sintering procedure. Previous studies have used a slurry of β -TCP and potato starch to produce α -TCP that was in a thermodynamically stable phase at temperatures above 1,100 $^{\circ}$ C.¹⁶ Uchino et al. found that HA formation is rarely observed on the surface of porous α -TCP

ceramics with 80% porosity.¹⁷ In this study, a comparison of the scatter plot data of the synthesized α -TCP particles with that of α -TCP data registered with the Joint Committee on Powder Diffraction Standards confirmed that these peaks appeared at the same angles. In addition, the Ca/P ratio of the product was 1.5, which fulfilled the requirements of the ASTM standards.¹⁸

Basic animal research on sinus lift has been conducted on dogs, sheep and rabbits.^{12, 19, 20} The canine frontal sinus is a size closer to the human maxillary sinus and allows accurate control of a large number of experimental models. In addition, the canine frontal sinus is the largest among the canine paranasal sinuses and the canine sinus wall is covered with multiple rows of ciliated columnar epithelium, as is the human maxillary sinus.²¹ Moreover, the surgeon can approach both sides of the frontal sinus through a single incision because the left and right frontal sinuses are adjacent to each other.

In the edentulous jaw and sinus-alveolar crest, the distance between the sinus and the alveolar bone is important in terms of implant treatment. A bone height of around 20 mm is required for dental implant treatment; therefore, sinus surgery is expected to promote bone formation to a height of more than 20 mm.²² Since the vertical length of the human maxillary sinus is about 28 mm, the top of the implant projects from the maxillary sinus floor into the elevation space of 20 mm.²¹ In this experiment, the top of the implant projected into the canine frontal sinuses. Therefore, the canine frontal sinus was considered a suitable experimental model of sinus surgery.

The biological behavior of α -TCP-based biomaterials has been analyzed in several *in vivo* studies.²³⁻²⁵ Kihara et al. performed an *in vivo* test using a rat model to observe the biodegradation process of particles (~300 μ m diameter) of pure α -TCP and found that the residual α -TCP particles degraded without decreasing the volume of the transplantation region.²⁶ Our previous study evaluated the effects of combining poly(Pro-Hyp-Gly) and α -TCP particles on bone formation in a canine tibial defect model.²³ These particles did not induce inflammation; moreover, complete degradation and remodeling of the lamellar bone were observed with their use. This, to our knowledge, is the first study to investigate the effects of porous α -TCP as a tissue-engineered scaffold for maxillary sinus augmentation in a canine model. Although histological images showed high levels of porous

α -TCP at four weeks, new bone formation had already started. Moreover, the porous α -TCP particles had been completely absorbed and replaced with new bone at 12 weeks. New bone formation in the area of the bone window reduced between 12 and 24 weeks. No bone exists originally in the area of the bone window; thus, the newly formed bone will be absorbed over time. Mechanical stresses, such as occlusion, may inhibit the absorption of the newly formed bone. Although β -TCP was an acceptable bone substitute material for augmenting maxillary sinus bone formation, it was likely to continue increasing and would have been progressively replaced over a longer time.²⁷ However, prolonged bone augmentation is disadvantageous.

Conclusion

Sinus floor augmentation is a safe and elegant surgical procedure before implant insertion. The porous α -TCP tested is a biocompatible, osteoconductive material that promotes new bone formation when used with integrated Ti implants, as demonstrated in this study on a canine frontal sinus model. However, the effectiveness and safety of this method need to be further evaluated before it can be clinically applicable.

Competing interests

The authors declare no conflicts of interest.

Acknowledgments

This work was funded by the Promotion and Mutual Aid Corporation for Private Schools of Japan's Science Research Promotion Fund (Tokyo, Japan; No. 15-09).

References

1. Acocella A, Bertolai R, Nissan J, Sacco R. Clinical, histological and histomorphometrical study of maxillary sinus augmentation using cortico-cancellous fresh frozen bone chips. *J Craniomaxillofac Surg.* 2011 Apr;39(3):192–9.
2. Summers RB. A new concept in maxillary implant surgery: the osteotome technique. *Compendium.* 1994 Feb;15(2):152, 154–6, 158 passim; quiz 162.
3. Wetzel AC, Stich H, Caffesse RG. Bone apposition onto oral implants in the sinus area filled with different grafting materials. A histological study in beagle dogs. *Clin Oral Implants Res.* 1995 Sep;6(3):155–63.
4. Zhang Y, Tangl S, Huber CD, Lin Y, Qiu L, Rausch-Fan X. Effects of Choukroun's platelet-rich fibrin on bone regeneration in combination with deproteinized bovine bone mineral in maxillary sinus augmentation: a histological and histomorphometric study. *J Craniomaxillofac Surg.* 2012 Jun;40(4):321–8.
5. Sakai K, Hashimoto Y, Baba S, Nishiura A, Matsumoto N. Effects on bone regeneration when collagen model polypeptides are combined with various sizes of alpha-tricalcium phosphate particles. *Dent Mater J.* 2011 Nov;30(6):913–22.
6. Weiland AJ, Phillips TW, Randolph MA. Bone grafts: a radiologic, histologic, and biomechanical model comparing autografts, allografts, and free vascularized bone grafts. *Plast Reconstr Surg.* 1984 Sep;74(3):368–79.
7. Goto T, Kojima T, Iijima T, Yokokura S, Kawano H, Yamamoto A, Matsuda K. Resorption of synthetic porous hydroxyapatite and replacement by newly formed bone. *J Orthop Sci.* 2001 Jun;6(5):444–7.
8. Velich N, Németh Z, Hrabák K, Suba Z, Szabó G. Repair of bony defect with combination biomaterials. *J Craniomaxillofac Surg.* 2004 Jun;15(1):11–5.
9. Yamada K, Umeda M, Komori T, Kawai T. Influence of hydroxyapatite (HA) chemical composition on solubility behavior and bone formation. *Kokubyo Gakkai Zasshi.* 2001 Jun;50(2):90–7.
10. Chidylo SA, Marschall MA. Porous hydroxyapatite and tissue infection. *Plast Reconstr Surg.* 1992 Jun;90(1):146–7.
11. Rosen HM. The response of porous hydroxyapatite to contiguous tissue infection. *Plast Reconstr Surg.* 1991 Dec;88(6):1076–80.
12. Haas R, Donath K, Födinger M, Watzek G. Bovine hydroxyapatite for maxillary sinus grafting: comparative histomorphometric findings in sheep. *Clin Oral Implants Res.* 1998 Apr;9(2):107–16.
13. Matsuno T, Nakamura T, Kuremoto K, Notazawa S, Nakahara T, Hashimoto Y, Satoh T, Shimizu Y. Development of beta-tricalcium phosphate/collagen sponge composite for bone regeneration. *Dent Mater J.* 2006 Mar;25(1):138–44.
14. Carrodeguas R, De Aza S. α -Tricalcium phosphate: synthesis, properties and biomedical applications. *Acta Biomater.* 2011 Oct;7(10):3536–46.
15. Marukawa K, Ueki K, Okabe K, Nakagawa K, Yamamoto E. Use of self-setting α -tricalcium phosphate for maxillary sinus augmentation in rabbit. *Clin Oral Implants Res.* 2011 Jun;22(6):606–12.
16. Kitamura M, Ohtsuki C, Iwasaki H, Ogata SI, Tanihara M, Miyazaki T. The controlled resorption of porous α -tricalcium phosphate using a hydroxypropylcellulose coating. *J Mater Sci Mater Med.* 2004 Oct;15(10):1153–8.
17. Uchino T, Ohtsuki C, Kamitakahara M, Tanihara M, Miyazaki T. Apatite formation behavior on tricalcium phosphate (TCP) porous body in a simulated body fluid. *Key Eng Mater.* 2006 Jun;309–11:251–4.
18. Carrodeguas RG, De Aza S. α -Tricalcium phosphate: synthesis, properties and biomedical applications. *Acta Biomater.* 2011 Oct;7(10):3536–46.
19. Jeong SM, Lee CU, Son JS, Oh JH, Fang Y, Choi BH. Simultaneous sinus lift and implantation using platelet-rich fibrin as sole grafting material. *J Craniomaxillofac Surg.* 2014 Sep;42(6):990–4.
20. Watanabe K, Niimi A, Ueda M. Autogenous bone grafts in the rabbit maxillary sinus. *Oral Surg Oral Med Oral Pathol Radiol Endod.* 1999 Jul;88(1):26–32.
21. Shimizu H, Watanabe T, Sato J. [An animal experiment using dog frontal sinuses for histological consideration of the maxillary sinus augmentation surgery for implants]. *Tsurumi Shigaku.* 2003 Jan;29(1):37–56. Japanese.
22. Tatum OH Jr, Lebowitz MS, Tatum CA, Borgner R. Sinus augmentation. Rationale, development, long-term results. *N Y State Dent J.* 1993 May;59(5):43–8.
23. Ito T, Hashimoto Y, Baba S, Iseki T, Morita S. Bone regeneration with a collagen model polypeptides/ α -tricalcium phosphate sponge in a canine tibia defect model. *Implant Dent.* 2015 Apr;24(2):197–203.
24. Li P, Hashimoto Y, Honda Y, Nakayama Y, Kobayashi N, Hara E, Yasui K, Arima Y, Matsumoto N. Evaluation of bone regeneration by porous alpha-tricalcium phosphate/atelocollagen sponge composite in critical-sized rat calvarial defects. *J Hard Tissue Biol.* 2016 Jun;25(1):35–40.
25. Tokuda T, Honda Y, Hashimoto Y, Matsumoto N. Comparison of the bone forming ability of different sized- α -tricalcium phosphate granules using a critical size defect model of the mouse calvaria. *Nano Biomed.* 2015 Dec;7(2):63–71.
26. Kihara H, Shiota M, Yamashita Y, Kasugai S. Biodegradation process of α -TCP particles and new bone formation in a rabbit cranial defect model. *J Biomed Mater Res B Appl Biomater.* 2006 Nov;79(2):284–91.
27. Zerbo IR, Zijderveld SA, De Boer A, Bronckers AL, De Lange G, Ten Bruggenkate CM, Burger EH. Histomorphometry of human sinus floor augmentation using a porous β -tricalcium phosphate: a prospective study. *Clin Oral Implants Res.* 2004 Dec;15(6):724–32.